

## Lymphatic Drainage Patterns from the Treated Breast

Iris M. C. van der Ploeg<sup>1</sup>, Hester S. A. Oldenburg<sup>1</sup>, Emiel J. T. Rutgers<sup>1</sup>, Marie-Jeanne T. F. D. Baas-Vrancken Peeters<sup>1</sup>, Bin B. R. Kroon<sup>1</sup>, Renato A. Valdés Olmos<sup>2</sup>, and Omgo E. Nieweg<sup>1</sup>

<sup>1</sup>Department of Surgery, The Netherlands Cancer Institute - Antoni van Leeuwenhoek Hospital, Amsterdam, The Netherlands; <sup>2</sup>Department of Nuclear Medicine, The Netherlands Cancer Institute - Antoni van Leeuwenhoek Hospital, Amsterdam, The Netherlands

### ABSTRACT

**Introduction.** Lymphatic drainage patterns from the breast have been described in the past. Drainage may change after treatment of a breast or axilla, and this may have implications for lymphatic mapping. The aim of this study was to determine the lymphatic drainage patterns in breast cancer patients with a previously treated ipsilateral breast.

**Methods.** Between January 1999 and November 2008, 115 sentinel node procedures were performed in breast cancer patients who had undergone treatment of the ipsilateral breast in the past. Lymphatic drainage patterns were analyzed based on preoperative lymphoscintigraphy and sentinel lymph node biopsy. Patients were divided into subgroups according to their previous treatment.

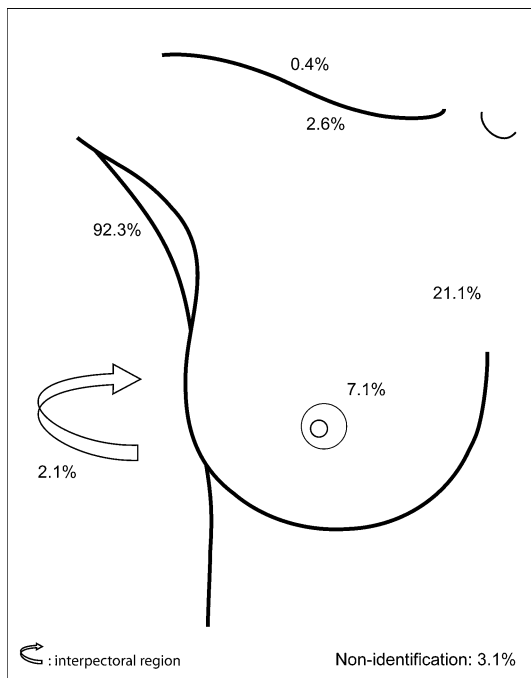
**Results.** Sentinel nodes were found in 84% of the patients: in 81 patients (70%) in the axilla, 43 patients (37%) had drainage to more than one site, and in 18 patients (16%) no drainage was detected. The percentage of drainage outside the axilla was higher than in a series of untreated breast cancer patients from our institution (51% versus 33%,  $P = 0.01$ ). The 16% nonidentification rate was also higher than the 3.1% in patients without previous treatment ( $P = 0.003$ ). Four patients (3.5%) had lymphatic drainage to the contralateral axilla. Twelve patients (10%) had involved sentinel nodes; these were harvested from the contralateral axilla in two of them. No lymph node recurrences were observed during a median follow-up time of 39 months.

**Conclusion.** Lymphatic mapping yields a lymph node in 84% of breast cancer patients who have undergone previous treatment of the breast. Nonidentification and extra-axillary nodes are more frequently encountered than in patients without treatment of the breast in the past. The finding of involved nodes suggests that sentinel node biopsy improves staging. Long-term follow-up will determine the sensitivity of the procedure in this specific situation.

The sentinel node procedure can be considered standard of care in the management of primary breast cancer.<sup>1–4</sup> At The Netherlands Cancer Institute, the intratumoral tracer-injection technique is used for lymphatic mapping to accurately visualize lymphatic drainage from the actual breast cancer.<sup>5</sup> This approach has shown that more than one-quarter of patients have sentinel lymph nodes in and around the breast outside the axilla.<sup>6–8</sup>

The incidence of second primary and recurrent ipsilateral breast cancer has increased since the introduction of breast-conserving therapy.<sup>9,10</sup> Most surgeons would perform axillary lymph node dissection in such patients if this has not yet been done.<sup>11,12</sup> Surgeons have been reluctant to perform lymphatic mapping because of fear that the previous treatment has changed the lymphatic flow and that the wrong node will be removed, which may lead to a false-negative procedure.<sup>13,14</sup> Several studies have suggested the opposite, indicating that lymphatic mapping is feasible in patients with a recurrence or a second primary breast cancer, although sensitivity has not yet been reliably established.<sup>15–18</sup>

The aim of this study was to determine the lymphatic drainage routes from the breast to the axillary and extra-axillary sentinel lymph nodes in breast cancer patients who have previously undergone a surgical procedure with or without radiotherapy of the same breast and often the



**FIG. 1** Lymphatic drainage pattern of 700 primary breast cancer patients, calculated from the results of a previous study.<sup>6</sup> Lymphatic drainage was observed towards sentinel nodes in the axilla (level I and II), the internal mammary chain, the breast, the interpectoral region, the infraclavicular fossa (level III), and the supraclavicular region

axilla. Four different subcategories were analyzed based on the type of previous treatment. The results were compared with the drainage patterns in patients without a breast procedure in the past, who have recently been studied at our institution (Fig. 1).<sup>6</sup>

## PATIENTS AND METHODS

The study population consisted of 115 patients, which is 5.3% of the 2,154 breast cancer patients who underwent sentinel node biopsy between January 1999 and November 2008. One patient with bilateral recurrent breast cancer after previous bilateral breast-conserving treatment was included twice, once for each breast. Two patients with a previously treated breast were not included in the study because they did not fit the subgroup analyses. One of the two was the only patient who had undergone a previous modified radical mastectomy, and the other patient was the only one in whom a major pectoral muscle flap was used to reconstruct a defect after resection of a squamous cell carcinoma in the neck. The median age of the patients was 57 years (range 19–85 years). Pathological proof of breast cancer was obtained in all patients.

A 2-day protocol was used for the sentinel node procedure. On the first day, an intratumoral injection of 120 MBq technetium-99 m nanocolloid (Nanocoll<sup>®</sup>,

GE-Healthcare, Eindhoven, The Netherlands) was given in a volume of 0.2 ml. Static images were obtained at 10 min, 2 h, and 4 h after radiotracer administration. A dual-head gamma camera equipped with low-energy high-resolution collimators (Vertex<sup>®</sup>, Philips, Eindhoven, The Netherlands) was used for imaging. Both anterior and lateral images were routinely obtained and additional images if needed. A cobalt-57 flood source was placed behind the patient to outline the body contour. A sentinel node was defined as a lymph node upon which the primary tumor drains directly.<sup>19</sup>

Single-photon emission computed tomography with CT scanning (SPECT/CT) was introduced in December 2006 and was performed when conventional images failed to visualize a sentinel node in the axilla.<sup>20</sup> SPECT/CT was performed immediately after the 4-h conventional images using a hybrid system (Symbia T, Siemens, Erlangen, Germany) without re-injection of the radiopharmaceutical. After correction for attenuation and scatter, fused SPECT/CT images were generated and displayed in both two- and three-dimensional projections for anatomical localization of sentinel nodes and surrounding tissues. The location of a sentinel node was marked on the skin with indelible ink. A second dosage of the radiopharmaceutical was given in case of nonvisualization, and conventional lymphoscintigraphy was repeated.

The next day, 1 ml patent blue dye (Laboratoire Guerbet, Aulnay-Sous-Bois, France) was administered in the breast cancer immediately before the operation. Sentinel nodes were pursued in the axilla and in all other regions indicated by lymphoscintigraphy. All harvested lymph nodes were fixed in formalin, bisected, embedded in paraffin, and cut at a minimum of six levels at 50- to 150- $\mu$ m intervals. Pathological evaluation included hematoxylin-eosin and immunohistochemical staining (CAM 5.2; Becton Dickinson, San Jose, CA, USA). Axillary node dissection was only performed if an involved sentinel node was found in the axilla.

The patients were followed at our own institution with particular attention to the lymph node fields, using ultrasound if necessary. The median follow-up duration was 39 months (range 1–117 months).

The patient population was examined as a whole but was also divided into the following four subgroups according to previous treatment of the breast. Thirty-six patients (31%) had previously undergone breast-conserving treatment with sentinel node biopsy but without axillary node dissection. A median of two sentinel nodes were identified per patient with a maximum of six in this first sentinel node procedure. The second subgroup consisted of 12 patients (10%) who had undergone breast-conserving treatment with axillary node dissection. Radiotherapy is a part of breast-conserving therapy and in 24 of these patients the axilla had been

included in the radiation field. None of the patients received radiotherapy to the internal mammary chain. In the third subgroup, 57 patients (50%) were included in whom only excisional biopsy had been performed, in 19 for a benign lesion and in 38 for ductal carcinoma in situ. All previously performed excisional biopsies had therapeutic intent. The patients with carcinoma in situ in the biopsy specimen all underwent radical excision of their lesion and all lesions were low- or intermediate-grade carcinoma in situ and none underwent radiotherapy. The fourth subgroup consisted of ten patients (9%) who had undergone plastic surgery. Four of them had received breast reduction, and breast augmentation had been carried out in six.

Patient characteristics, lymphoscintigraphy results, operative findings, and outcome were recorded prospectively. The median interval between the first treatment and the sentinel node biopsy that was the subject of the study was 79 months with a range of 22 days to 427 months. The 22-day interval concerned a patient who underwent a breast reduction 22 days earlier. The lymphatic drainage patterns were analyzed for the whole study population and for each subgroup. The chi-squared test or the Fisher exact test was performed to evaluate differences in drainage between various patient groups. Statistical analyses were performed by using SPSS 15 (version 15, SPSS Inc., Chicago, IL) for Windows.

## RESULTS

Preoperative lymphoscintigraphy revealed 183 sentinel nodes in 96 of the 115 patients (83%) who had undergone previous treatment of the same breast. All visualized sentinel nodes were harvested. Surgical exploration using blue dye and the gamma ray detection probe yielded 12 additional axillary sentinel nodes in nine patients in whom no node in the axilla had been visualized preoperatively. In the end, lymphatic drainage was observed in 97 patients (84%). A median of two sentinel nodes were identified per patient with a maximum of five.

Sentinel nodes were found in level I and II of the axilla in 81 patients (70%), and 43 patients (37%) had drainage to more than one site (Table 1; Fig. 2). Lymphatic drainage to the contralateral axilla was seen in four patients (3.5%). Sentinel nodes were more often found outside the axilla compared with in patients in our earlier study in whom no previous treatment of the breast had been carried out (51% versus 33%,  $P = 0.01$ ) and the nonidentification rate was also higher (16% versus 3%,  $P = 0.003$ ).<sup>6</sup>

The lymphatic drainage patterns in the four subgroups according to type of previous treatment are shown in Figs. 3, 4, 5 and 6. Sentinel nodes in the axilla were most often found in patients who had undergone only excisional

**TABLE 1** Lymphatic drainage patterns in all 137 patients with a previously treated breast

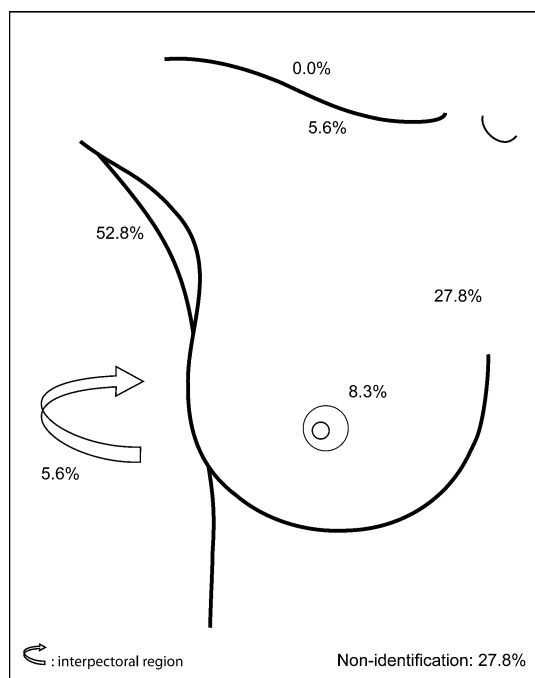
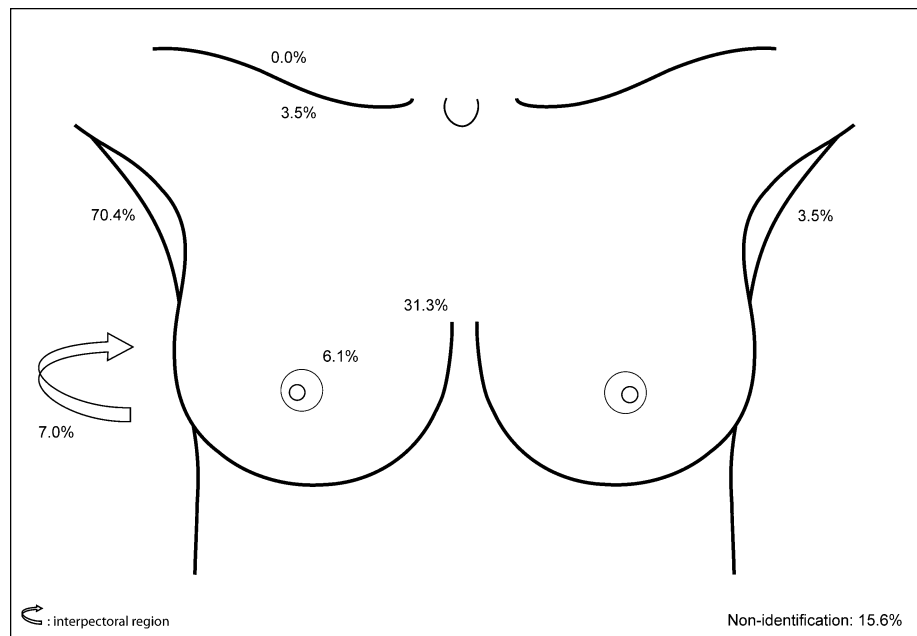
Drainage pattern	Number (%)
Nonidentification	18 (16)
Axilla only	49 (43)
Outside axilla only	12 (10)
Internal mammary chain	9 (8)
Interpectoral fossa	2 (2)
Internal mammary chain and infraclavicular fossa	1 (1)
Axillary and elsewhere	32 (28)
Axilla and internal mammary chain	18 (16)
Axilla and infraclavicular fossa	1 (1)
Axilla and breast	5 (4)
Axilla and interpectoral fossa	5 (4)
Axilla, internal mammary chain, and infraclavicular fossa	1 (1)
Axilla, internal mammary chain, and breast	1 (1)
Axilla, internal mammary chain, and interpectoral fossa	1 (1)
Axilla, infraclavicular fossa, and interpectoral fossa	1 (1)
Contralateral drainage	4 (3)
Contralateral axilla	3 (3)
Contralateral axilla and ipsilateral internal mammary chain	1 (1)
Total	115 (100)

biopsy of the breast (91%) (Fig. 5) or plastic surgery (100%) (Fig. 6). Sentinel nodes were detected in the axilla in 25% of the patients in whom axillary dissection had been carried out in the past (Fig. 4). The percentage of extra-axillary drainage was highest (60%) in patients who had undergone plastic surgery. This was higher than the 51% of sentinel nodes outside the axilla in the whole study population ( $P = 0.04$ ). Internal mammary sentinel nodes were seen in 17% of the patients who had undergone breast-conserving treatment with axillary node dissection. The rates of extra-axillary drainage were comparable in the other subgroups: 47% after breast-conserving treatment with just sentinel node biopsy and 44% after excisional biopsy of the breast.

Nonidentification was most often seen in patients after breast-conserving therapy: 28% in patients who had undergone sentinel node biopsy and 50% in patients in whom axillary dissection had been performed. These rates were higher than the 15% in the whole study population ( $P = 0.01$  and  $P = 0.003$ , respectively).

Fourteen sentinel nodes were tumor-positive in 12 patients (10%). In ten patients, the positive sentinel node was harvested from the axilla and prompted completion dissection. The two other patients had previously undergone an axillary dissection and now had a positive sentinel

**FIG. 2** Location and incidence of sentinel nodes in all 137 patients. Lymphatic drainage was observed towards sentinel nodes in the axilla (level I and II), the internal mammary chain, the breast, the interpectoral region, the infraclavicular fossa (level III), the supraclavicular region, and the contralateral axilla



**FIG. 3** Location and incidence of sentinel nodes in 36 patients after previous breast-conserving treatment with sentinel node biopsy but without axillary node dissection

node in the contralateral axilla. They were subjected to axillary node dissection on that side and are alive and free of disease 22 and 36 months after sentinel node biopsy.

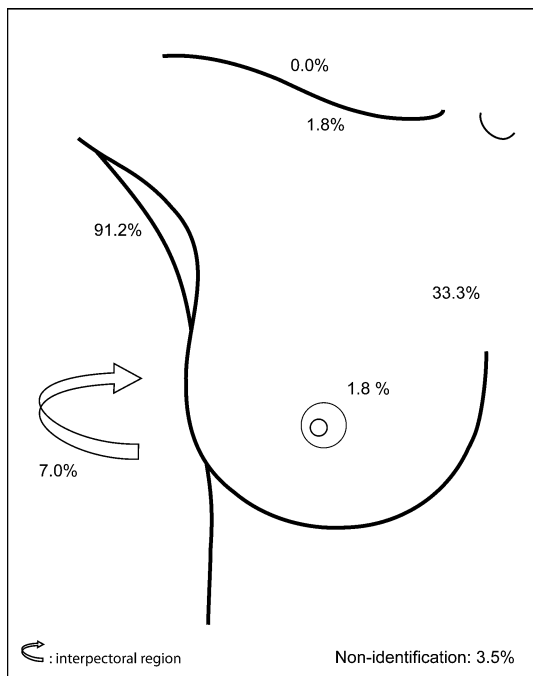
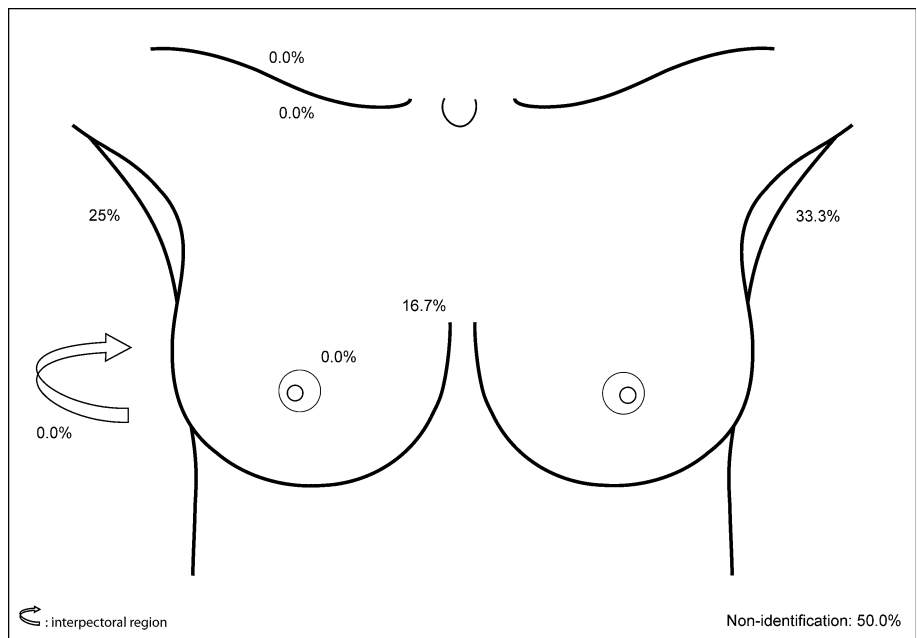
No lymph node recurrences were detected in or outside the axillae during follow-up (median 39 months).

## DISCUSSION

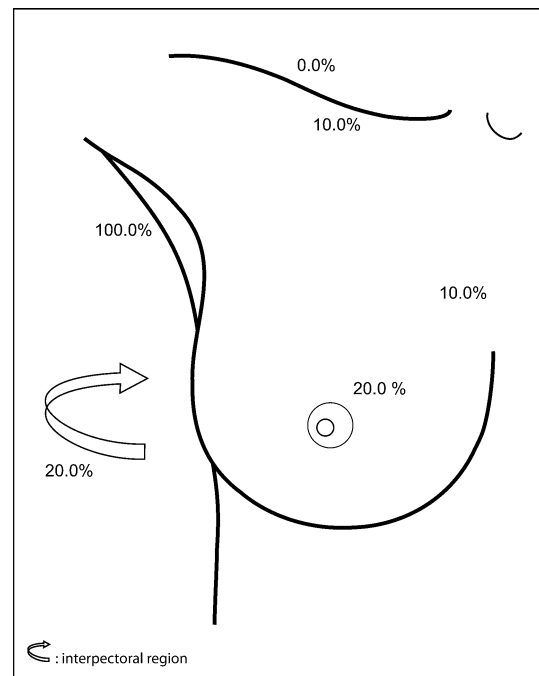
The sentinel node detection rate in this study describing breast cancer patients with a previously treated breast and/or axilla was 84%. This percentage falls in the range of 62–100% described in studies of similar populations of breast cancer patients.<sup>15–18,21–25</sup> Whereas drainage to the axilla is normally present in approximately 95% of untreated breast cancer patients, this was 70% in the present study population. In the subgroups of patients in whom no axillary node dissection had been done this was 53–100%. The 51% incidence of drainage to nodes outside the axilla was higher than the 33% in patients without a breast operation in the past. The incidence of extra-axillary drainage after prior treatment mentioned in literature ranges between 29% and 67%.<sup>16–18,21,22,25</sup> Newman et al. identified extra-axillary drainage in 67% of ten patients with a previously treated breast who had undergone sentinel node biopsy without confirmative completion dissection, whereas this was 15% in 117 patients without previous treatment ( $P = 0.001$ ).<sup>25</sup> In a study by Port et al., 30% of 41 patients who had received sentinel node biopsy without further dissection had extra-axillary drainage, versus 6% in those without previous treatment ( $P < 0.0001$ ).<sup>16</sup> Two studies showed a correlation between the number of previously excised axillary lymph nodes and a subsequent higher incidence of alternative lymphatic drainage and nonvisualization.<sup>16,22</sup>

An important finding was the observation of contralateral drainage, which was found in 4 of the 12 patients who had undergone previous axillary node dissection. The relevance of contralateral axillary sentinel nodes is

**FIG. 4** Location and incidence of sentinel nodes in 12 patients after previous breast-conserving treatment with axillary node dissection



**FIG. 5** Location and incidence of sentinel nodes after previous excisional biopsy



**FIG. 6** Location and incidence of sentinel nodes after previous plastic surgery

demonstrated by the fact that these were involved in two of the four patients. Contralateral axillary drainage was studied by Perre et al. in 23 breast cancer patients from our institution by performing lymphoscintigraphy before and 6 months after axillary dissection or axillary radiotherapy. Before treatment, uptake of radioactivity was seen in 20 patients, of whom 1 had contralateral drainage. After

treatment, uptake was visualized in only 11 patients, of whom 6 had contralateral drainage.<sup>13</sup> Roumen et al. described sentinel nodes in the other axilla after previous axillary node dissection in four patients with a local recurrence, of whom two were tumor-positive.<sup>17</sup> The 2006 American Joint Committee on Cancer (AJCC) staging system classifies contralateral lymph node metastasis as

distant disease (stage IV).<sup>26</sup> This appears appropriate in case of a primary cancer in an untreated breast, because contralateral metastasis signifies dissemination beyond the regional nodes. However, this may not be the case in the situation under review. Contralateral disease after axillary node dissection may simply reflect regional dissemination to the node on the direct drainage pathway, requiring a therapeutic dissection of the affected axilla. The published incidence of contralateral drainage in previously treated breast cancer patients ranges from 20% to 46%.<sup>16–18,21</sup> The majority of these contralateral metastases occur after a previous axillary lymph node dissection.<sup>17,18,27</sup> Investigators at the John Wayne Cancer Institute mentioned contralateral sentinel nodes in 3 of 11 patients with a recurrence who all had undergone axillary dissection, and in two cases these were involved.<sup>18</sup> Koizumi et al. found drainage to the opposite axilla in seven out of ten patients and suggested this to be related to radiation of the breast as a part of the prior breast-conserving therapy.<sup>15</sup> Only two of these ten patients had undergone axillary dissection.

In the analysis of the subgroups, the finding that drainage to level I or II of the axilla was observed in 25% of the patients after axillary dissection is remarkable. The subgroup of patients who had undergone breast-conserving therapy and sentinel node biopsy had a relatively high incidence (47%) of sentinel nodes outside the axilla, but the patients who had undergone additional axillary node dissection had a low rate (17%) of sentinel nodes elsewhere. Nonidentification of sentinel nodes in the present series was most often seen following previous sentinel node biopsy (28%) and after axillary node dissection (50%). There are no other studies on the sentinel node detection rate in patients after previous breast augmentation or reduction. In all ten such patients, we observed drainage from the cancer to a node.

No lymph node recurrences were detected in a relatively short median follow-up time of 39 months. Intra and coworkers had no false-negative sentinel node procedures in 18 patients with a median follow-up duration of 13 months.<sup>23</sup> Port et al. encountered no lymph node recurrence after a previous operation in 64 patients who were followed for a mean of 2.2 years.<sup>16</sup> However, 2 of the 23 patients who underwent completion dissection in spite of a tumor-free axillary sentinel node were found to have additional nodal involvement (9%). Luini et al. encountered four lymph node recurrences following sentinel node biopsy after previous surgery in a study with median follow-up of 2 years.<sup>24</sup> This translates into a recurrence rate of 5%, which is high compared with a median recurrence rate of 0.3% in sentinel node patients without previous treatment.<sup>7,28</sup> These observations illustrate that, although a “sentinel” node can be found, it is unclear whether it is the very node upon which the primary tumor has always

drained. This issue is indeed poignant, since a study comparing lymphoscintigrams before and shortly after excision of a breast lesion showed a different drainage pattern in 68% of patients.<sup>29</sup>

We conclude that, compared with untreated breasts, lymph drainage from cancer in a previously treated breast occurs less often to the axilla (70% versus 92%) and more often to nodes elsewhere (51% versus 33%), as far away as the contralateral axilla (3.5%). A sentinel node can be identified in 84% of the patients. Pursuing extra-axillary sentinel nodes improves staging. The lymphatic drainage pattern was to some extent dependent on the type of previous therapy of the breast.

Compared with the former situation, in which it was standard to perform axillary dissection, a considerable number of patients were spared this operation. Also, in the former situation valuable staging information would have been missed.

If a positive node is found, the procedure obviously contributes to staging, but how reliable is a node that is disease free? Did the tumor perhaps drain to another node before the previous treatment of the breast? The low percentage (10%) of patients with involved nodes makes one wonder. The absence of lymph node recurrences during our median follow-up time of 39 months does not reliably assess the sensitivity. Wright et al. demonstrated that the average recurrence in the axilla after axillary node dissection is seen after more than 6 years, illustrating that long-term follow-up is needed to determine the sensitivity of sentinel node biopsy.<sup>30</sup> The currently available evidence suggests that sensitivity may be less than in untreated patients.<sup>16,24,29</sup> Lymphatic mapping is probably most reliable in patients in whom the drainage pathways have not been disturbed since the breast cancer developed, or at least since it reached the stage where dissemination becomes a threat.

## REFERENCES

1. Sobin LH, Wittekind C, editors. TNM Classification of malignant tumours. Sixth edition. New York: Wiley; 2002.
2. Mansel RE, Fallowfield L, Kissin M, et al. Randomized multicenter trial of sentinel node biopsy versus standard axillary treatment in operable breast cancer: the ALMANAC Trial. *J Natl Cancer Inst.* 2006;98:599–609.
3. Schrenk P, Rieger R, Shamiyeh A, et al. Morbidity following sentinel lymph node biopsy versus axillary lymph node dissection for patients with breast carcinoma. *Cancer.* 2000;88:608–14.
4. Veronesi U, Paganelli G, Viale G, et al. A randomized comparison of sentinel-node biopsy with routine axillary dissection in breast cancer. *N Engl J Med.* 2003;349:546–53.
5. Nieweg OE, Estourgie SH, Valdés Olmos RA, et al. Lymphatic mapping with tracer administration into the primary breast cancer. *Eur J Surg Oncol.* 2003;29:95–7.
6. Estourgie SH, Nieweg OE, Valdés Olmos RA, et al. Lymphatic drainage patterns from the breast. *Ann Surg.* 2004;239:232–7.

7. Van der Ploeg IMC, Kroon BBR, Antonini N, et al. Axillary and extra-axillary lymph node recurrences after a tumor-negative sentinel node biopsy for breast cancer using intralesional tracer administration. *Ann Surg Oncol.* 2008;15:1025–31.
8. Van Rijk MC, Tanis PJ, Nieweg OE, et al. Clinical implications of sentinel nodes outside the axilla and internal mammary chain in patients with breast cancer. *J Surg Oncol.* 2006;94:281–6.
9. Fisher B, Bryant J, Dignam JJ, et al. Tamoxifen, radiation therapy, or both for prevention of ipsilateral breast tumor recurrence after lumpectomy in women with invasive breast cancers of one centimeter or less. *J Clin Oncol.* 2002;20:4141–9.
10. Veronesi U, Cascinelli N, Mariani L, et al. Twenty-year follow-up of a randomized study comparing breast-conserving surgery with radical mastectomy for early breast cancer. *N Engl J Med.* 2002;347:1227–32.
11. Osborne MP, Simmons RM. Salvage surgery for recurrence after breast conservation. *World J Surg.* 1994;18:93–7.
12. Margolese RG. Surgical considerations for invasive breast cancer. *Surg Clin North Am.* 1999;79:1031–46.
13. Perre CI, Hoefnagel CA, Kroon BBR, et al. Altered lymphatic drainage after lymphadenectomy or radiotherapy of the axilla in patients with breast cancer. *Br J Surg.* 1996;83:1258.
14. Estourgie SH, Valdés Olmos RA, Nieweg OE. Reproducibility of sentinel node lymphoscintigraphy after excisional biopsy of breast lesions. *Eur J Nucl Med Mol Imaging.* 2004;31:296.
15. Koizumi M, Koyama M, Tada K, et al. The feasibility of sentinel node biopsy in the previously treated breast. *Eur J Surg Oncol.* 2008;34:365–8.
16. Port ER, Garcia-Etienne CA, Park J, et al. Reoperative sentinel lymph node biopsy: a new frontier in the management of ipsilateral breast tumor recurrence. *Ann Surg Oncol.* 2007;14:2209–14.
17. Roumen RM, Kuijt GP, Liem IH. Lymphatic mapping and sentinel node harvesting in patients with recurrent breast cancer. *Eur J Surg Oncol.* 2006;32:1076–81.
18. Taback B, Nguyen P, Hansen N, et al. Sentinel lymph node biopsy for local recurrence of breast cancer after breast-conserving therapy. *Ann Surg Oncol.* 2006;13:1099–104.
19. Nieweg OE, Tanis PJ, Kroon BBR. The definition of a sentinel node. *Ann Surg Oncol.* 2001;8:538–41.
20. Van der Ploeg IMC, Valdés Olmos RA, Nieweg OE, et al. The additional value of SPECT/CT in lymphatic mapping in breast cancer and melanoma. *J Nucl Med.* 2007;48:1756–60.
21. Axelsson CK, Jonsson PE. Sentinel lymph node biopsy in operations for recurrent breast cancer. *Eur J Surg Oncol.* 2008;34:626–30.
22. Boughey JC, Ross MI, Babiera GV, et al. Sentinel lymph node surgery in locally recurrent breast cancer. *Clin Breast Cancer.* 2006;7:248–53.
23. Intra M, Trifiro G, Viale G, et al. Second biopsy of axillary sentinel lymph node for reappearing breast cancer after previous sentinel lymph node biopsy. *Ann Surg Oncol.* 2005;12:895–9.
24. Luini A, Galimberti V, Gatti G, et al. The sentinel node biopsy after previous breast surgery: preliminary results on 543 patients treated at the European Institute of Oncology. *Breast Cancer Res Treat.* 2005;89:159–63.
25. Newman EA, Cimmino VM, Sabel MS, et al. Lymphatic mapping and sentinel lymph node biopsy for patients with local recurrence after breast-conservation therapy. *Ann Surg Oncol.* 2006;13:52–7.
26. American Joint Committee on Cancer: AJCC cancer staging manual, version 01.03.00. Philadelphia, PA: Lippincott-Raven; 2006.
27. Sood A, Youssef IM, Heiba SI, et al. Alternative lymphatic pathway after previous axillary node dissection in recurrent/primary breast cancer. *Clin Nucl Med.* 2004;29:698–702.
28. Van der Ploeg IMC, Nieweg OE, Van Rijk MC, et al. Axillary recurrence after a tumour-negative sentinel node biopsy in breast cancer patients: a systematic review and meta-analysis of the literature. *Eur J Surg Oncol.* 2008;34:1277–84.
29. Estourgie SH, Valdés Olmos RA, Nieweg OE, et al. Excision biopsy of breast lesions changes the pattern of lymphatic drainage. *Br J Surg.* 2007;94:1088–91.
30. Wright FC, Walker J, Law CH, et al. Outcomes after localized axillary node recurrence in breast cancer. *Ann Surg Oncol.* 2003;10:1054–8.