

ERRATUM

## Erratum to: The Combination of Surgery and Imatinib in GIST: A Reality for Localized Tumors at High Risk, an Open Issue for Metastatic Ones

Alessandro Gronchi, MD<sup>1</sup> and Chandrajit P. Raut, MD, Msc<sup>2,3,4</sup>

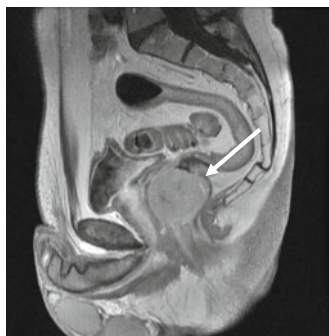<sup>1</sup>Department of Surgery, Sarcoma Service, Fondazione IRCCS Istituto Nazionale Tumori, Milan, Italy; <sup>2</sup>Department of Surgery, Brigham and Women's Hospital, Boston, MA; <sup>3</sup>Center for Sarcoma and Bone Oncology, Dana-Farber Cancer Institute, Boston, MA; <sup>4</sup>Harvard Medical School, Boston, MA

### ERRATUM TO: ANN SURG ONCOL DOI 10.1245/S10434-011-2191-4

In the original article, Fig. 2 was not published with the correct formatting.

The figure is reprinted here correctly.

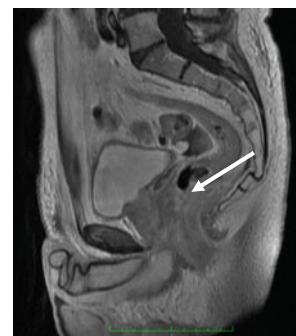
**FIG. 2** Contrast-enhanced magnetic resonance image of primary low rectal gastrointestinal stromal tumor before (*right*) and after (*left*) preoperative imatinib for 8 months. Because the tumor harbored an exon 9 mutation, the patient was treated with a higher dose. Surgery consisted of local excision rather than a formal low anterior resection



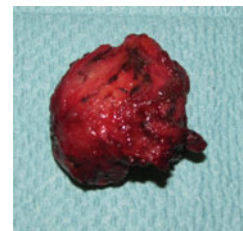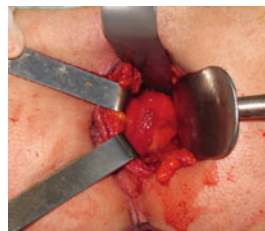
IM 800 mg/day  
x 8 mos



Kit exon 9 mutation



- Local excision through perineal approach



The online version of the original article can be found under doi:[10.1245/s10434-011-2191-4](https://doi.org/10.1245/s10434-011-2191-4).

© Society of Surgical Oncology 2012

Published Online: 1 February 2012

A. Gronchi, MD

e-mail: [alessandro.gronchi@istitutotumori.mi.it](mailto:alessandro.gronchi@istitutotumori.mi.it)