

The Classic

Congenital Dislocation of the Hip

A. M. Phelps MD

Published online: 29 February 2008

This month we highlight developmental dysplasia of the hip. The entity is one known since the beginning of recorded history, although until relatively recently it was known in the English language as congenital dislocation of the hip. Our Classic this month reproduces an article published in 1891 by AM Phelps describing a patient with an unusual congenital anterior dislocation of the hip and also outlines the then-current ideas regarding the etiology [1].

Despite considerable searching, I have unfortunately been able to uncover little information (including his first name) about this apparently prolific writer: he published at least 11 articles in the Transactions of the American Orthopaedic Association (later The Journal of Bone and Joint Surgery), and others in various journals such as Medical Record and the New England Journal of Medicine. All articles I could locate note he was from New York, but as was customary at the time, no additional information was provided regarding his address or institution or other contact information. According to records at the American Orthopaedic Association he was admitted in 1890 (only a few years after its founding in 1887) and he died in 1902. According to Weinstein [9], Phelps delivered the 1994 Presidential Address of the AOA, so he undoubtedly would have been prominent well before his induction into the AOA. Weinstein recognized Phelps' prescient thinking about the education of orthopaedists of the future: they would be "thoroughly schooled in all the departments of medicine...he will secure for our specialty the subjects which are rightfully ours...colleges will want professors of orthopedic surgery." (Readers will recognize Phelps was writing before the Flexner report resulted in more uniform medical schooling and at a time when orthopaedics was not

well established as a specialty and all training was via an apprenticeship system.)

Like most surgeons who focused on the musculoskeletal system at that time, Phelps had broad interests. He published a paper, "A New Operation of Hernia [4]," and according to Read [8], he reinforced hernia repairs with silver coils. However, he published on posterior congenital dislocation of the shoulder [5], surgical treatment of clubfoot [2], deformities of the knee [3], scoliosis [6], and infection [7]. Perhaps most astonishingly, he described the transplantation of tissue from lower animals to humans (found on Google ScholarTM without further reference).

In the article we reproduce this month, Phelps had the unusual (if unfortunate) opportunity to confirm the pathologic findings in his patient with an anteriorly dislocated hip: the patient died at age 4½ years from meningitis. The autopsy specimens (Figs 3 and 4) confirmed the anterior dislocation. It was common in those days to make inference of etiology based upon structural changes, many of which were secondary. Phelps cited Cornigan who "believed that the dislocation was a primary one, due to reflex spasm of the muscles in utero, caused by some central nerve lesion in early foetal life [1]." In referring to his case, he then remarked, "It seems to me that dislocation of this bone could not take place by the contraction of...muscles..." based on the directions of muscle pull.

Phelps summarized the then postulated causes of congenital dislocation of the hip. He quoted Ambrose Paré, from his book in 1678, "Hippocrates himself avers that infants in the very womb may have their joints dislocated by a fall, a blow, or compression [1]." "Heredity," Phelps commented, "no doubt has much to do with producing this deformity." He again cites Paré, on the role of heredity:

“...hereditary causes: ‘such as parents transfuse into their offspring; hence it is that crooked, not necessarily, but oftentimes, are generated by crooked, and lame by lame.’” Other causes he noted were “An original defect in the organization of the germ, or the operation of the formative power”; “Arrest of development of the cotyloid cavity”; “Certain articular maladies occurring in the fœtus during intrauterine life”; and “Diseases of the primitive nerve centers.” He concluded, “Congenital dislocation of the hip is produced, I believe, by injury at birth; injury in utero, or disease in utero; rachitis; hereditary influences, and in exceptional cases, if such there are, by arrest of development of the acetabulum.” Yet, “I am inclined to believe...that the deformity is more frequently produced by violence, or by pathological changes the result of inflammation, than from any other cause.” (Septic arthritis of the hip in those days was not an uncommon condition in infants and children, and often led to dislocation owing to delayed diagnosis and lack of proper treatment.)

Readers are encouraged to read the extensive Discussion at the end of the article. Undoubtedly, this paper was presented at the American Orthopaedic Association since it was published in the Transactions of the American Orthopaedic Association and discussed in detail. It was customary in those days to publish the remarks of individuals who raised questions or provided additional comments following presentation of the papers. Many of these comments are as informative as the papers themselves.

Richard A. Brand MD

Open Access This article is distributed under the terms of the Creative Commons Attribution Noncommercial License which

permits any noncommercial use, distribution, and reproduction in any medium, provided the original author(s) and source are credited.

References

1. Phelps AM. Congenital dislocation of the hip. *J Bone Joint Surg Am.* 1891;s1-4:132-147.
2. Phelps AM. The present status of the open incision method for talipes varo-equinus. *New Engl Med Mon.* 1891:217.
3. Phelps AM. Etiology of the deformities occurring in knee-joint disease. *J Bone Joint Surg Am.* 1894;s1-6:57-64.
4. Phelps AM. A new operation of hernia. *NY Med J.* 1894:1894.
5. Phelps AM. Congenital dislocation of the shoulder, its etiology and pathology, and an operation for its relief. *J Bone Joint Surg Am.* 1898;s1-11:202-204.
6. Phelps AM. Observations in lateral curvature of the spine: Pathological. Clinical. Mechanical. *J Bone Joint Surg Am.* 1900;s1-13:287-304.
7. Phelps AM. The treatment of abscesses of the joints with glass speculum, drainage and pure carbolic acid, with a report of seventy cases. *J Bone Joint Surg Am.* 1900;s1-13:13-24.
8. Read RC. Milestones in the history of hernia surgery: Prosthetic repair. *Hernia.* 2003;8:8-14.
9. Weinstein SL. The American Orthopaedic Association: critical choices. *J Bone Joint Surg Am.* 1997;79:1282-1289.

© The Association of Bone and Joint Surgeons 2008

(The Classic Article is ©1891 by the Journal of Bone and Joint Surgery, Inc., and is reprinted with courtesy from Phelps AM. Congenital dislocation of the hip. *J Bone Joint Surg Am.* 1891;s1-4:132-147.)

Richard A. Brand MD (✉)
Clinical Orthopaedics and Related Research,
1600 Spruce Street, Philadelphia,
PA 19103, USA
e-mail: dick.brand@clinorthop.org

Some two years ago Dr. John Ridlon, of New York, reported a case of congenital dislocation of the hip, the head of the bone resting on the pubes. This dislocation forward and upward is unusual. However, within a year, two other cases came to my clinic at the Post-Graduate Medical School and Hospital, with the same deformity.

The deformity in each case was precisely the same. They were, in fact, anterior and upward congenital dislocations of the head of the femur. The child, illustrated in this article, had always been healthy; there was no history of injury in the case; nor of any severe labor. The mother noticed that when the child began to walk, one leg was shorter than the other, and that the feet and toes were turned out. Figs. 1 and 2 are cuts made from photographs taken of the case when first seen. They show the outward rotation and shortening seen in anterior dislocation. The case was three years old when I first saw it. I applied a long traction

splint, which the child wore for a year and a half, when it died from acute meningitis. A post-mortem was permitted, and I have the specimen here, which with your permission I will now present.

Figs. 3 and 4 are drawings of the specimen made by Dr. Macdonald, and they very correctly represent the pathological condition found.

In the first specimen the head of the bone is seen above the rim of the acetabulum dislocated upward and forward. The capsule of the joint is cut away to give the view.

In Fig. 4 the acetabulum is seen to be angular in shape, small, and undeveloped, with the remains of the ligamentum teres. This specimen is of great interest, I believe, because so far as I know it is the only pathological specimen of anterior congenital dislocation of the hip reported, and it will be found of great value in studying the etiology of this deformity. It will be observed that the pressure of the

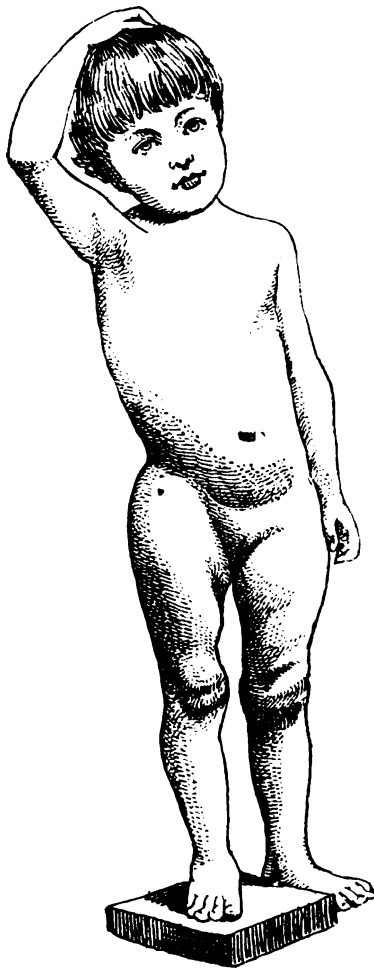


Fig. 1

head of the bone has changed the form of the anterior border of the acetabulum from concave to convex.

Etiology

It has been taught, and it is accepted by the profession generally in America and in England, that congenital dislocation of the hip is a secondary condition, depending upon the non-development of the acetabulum.

This specimen is surely a case of congenital dislocation primary, with non-development of the acetabulum from non-use.

I am not prepared to say that all cases are like this, but surely here is a case of congenital dislocation *in utero* not due to non-development of the acetabulum.

Dr. Cornigan, who, by the way, has written an excellent monograph on this subject, believed that the dislocation was a primary one, due to reflex spasm of the muscles *in utero*, caused by some central nerve lesion in early foetal life.

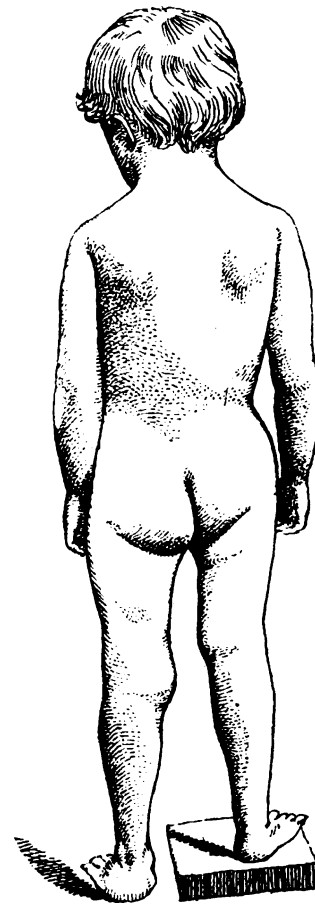


Fig. 2

A glance at the anatomy of the hip joint will show that the muscles pass diagonally across the body from the shaft of the femur to the pelvis, being in a line with the axis of the neck of the femur.

It seems to me that dislocation of this bone could not take place by the contraction of these muscles, but, on the contrary, that contraction of the glutei muscles, or of any of these groups, would tend to press the head of the bone more firmly into the acetabulum. A longcontinued spasm of muscle, sufficient to cut away the acetabulum, would destroy the head of the bone and produce a true inflammatory disease of the hip-joint.

Heredity, no doubt, has much to do with producing this deformity Dupuytren relates the history of a case—Marguerite Cardas—who had two aunts on the maternal side affected with lameness from their earliest attempt at walking. Marguerite's father had a sister lame from birth on the right side, who died at eighty years of age. Another sister, well formed, gave birth to a child with shortening of the right inferior extremity. This woman has a daughter by a healthy man with three inches of congenital shortening of the right leg. This girl also married a healthy man, but his father had a congenital dislocation of the right femur. She

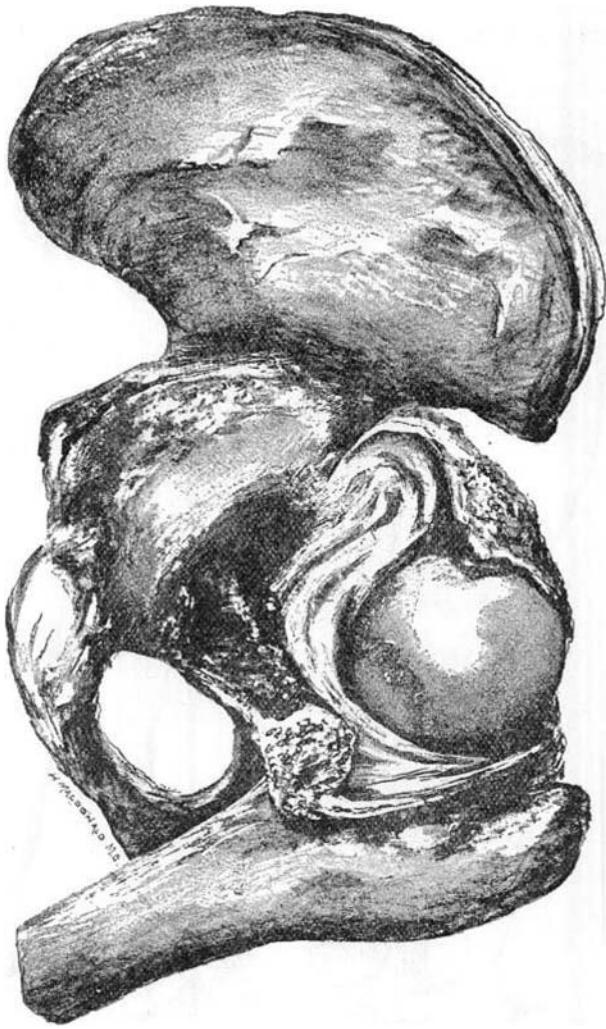


Fig. 3

has had four children, two of whom present the hereditary infirmity.

Similar cases are numerous, and it will be difficult to doubt that hereditary predisposition exerts some influence over the recurrence of this deformity in children whose parents or ancestors have been affected by it.

Ambrose Paré, 1678, book xvi., page 347, says of hereditary causes: "such as parents transfuse into their offspring; hence it is that crooked, not necessarily, but oftentimes, are generated by crooked, and lame by lame."

Also, "Hippocrates himself avers that infants in the very womb may have their joints dislocated by a fall, a blow, or compression." Among the other causes enumerated are:

1. An original defect in the organization of the germ, or the operation of the formative power. (By Dupuytren.) This hypothesis has no support in embryogeny.
2. Arrest of development of the cotyloid cavity. The pathological specimen here presented was certainly not produced by this cause.

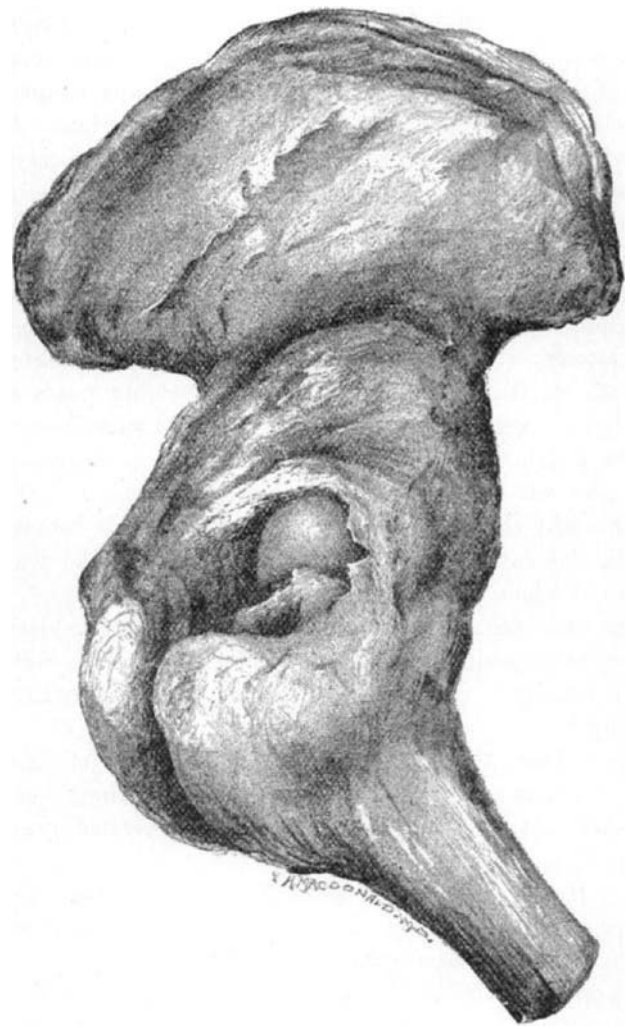

Fig. 4

3. Certain articular maladies occurring in the foetus during intra-uterine life. No doubt diseases of the joint might occur which would produce a diastasis or even the destruction of the acetabulum, leading to a dislocation.
4. Diseases of the primitive nerve centres are said to cause a perverted condition of the excito-motor apparatus of the medulla spinalis, producing a spasm of the muscle, and resulting in dislocation. This is the favorite theory of Dr. Cornigan and M. Guerin; but I have already stated that the anatomy of the joint is such that muscular spasm, independent of other causes, could not produce dislocation of the hip. It is true that in anencephalous foetal monsters congenital dislocation of the hip, club-foot, and other deformities are found, but there must be other pathological conditions present favoring these deformities, because many of those monstrosities have no deformity of the extremities whatever.

It seems to me that if spasm of the muscle *in utero* produces dislocation of the hip, it ought always to produce it in the same direction, but we find that the usual form is upon the dorsal of the ilium, and this specimen which I present is one upward and forward, and Dr. Cornigan says that the dislocation may take place downward and forward, or downward and backward.

These facts, together with the peculiar anatomy of the hip-joint and the direction in which the muscles operate upon the femur, lead me to believe that this is not one of the causes *per se* of congenital dislocation of the hip.

A few years ago I saw a child one hour after it was born. The right limb was an inch shorter than the left, and there was a dislocation on the dorsal of the ilium. I manipulated the limb in the usual method and reduced the dislocation, and the head remained in place without a retaining apparatus. This was clearly a case of dislocation which had taken place during confinement. If the deformity had not been noticed until the child began to walk, any physician would have said that this was a case of congenital dislocation of the hip.

Mr. C. B. Lockwood presented at the London Pathological Society two specimens of infants illustrating the absence of the margin of the acetabulum with and without displacement of the head of the femur. (See *Transactions of that Society*, 1887, vol. xxxviii., page 303.)

The first case is one of microcephalic foetus, probably born at full term; a case of double breech-presentation, and after birth the thighs remained flexed upon the abdomen. The pelvis was quite well formed, with the exception of the acetabulum. The cartilaginous rim of that socket was entirely absent, otherwise the joint was normal. The capsule was capacious; the ligamentum teres longer than usual. The head of the femur was normal, lying upon a flat surface.

The second case shows absence of the margin of the acetabulum with displacement of the head of the femur upon the dorsum of the ilium. This was a breech-presentation. After birth the thighs remained flexed upon the abdomen and the legs over-extended upon the thighs. There was an ectopium of the abdomen, with considerable protrusion of the viscera—of the liver, etc.

The brain and spinal cord seemed normal. The head of the radius was displaced on to the front surface of the ulna, and the carpus toward the flexor aspect of the radius and ulna; both hips were displaced upon the dorsum of the ilium, with changes of all structures entering into the formation of the joint. The head of the femur was irregular in shape. The cartilaginous margin of the acetabulum was absent, although the cotyloid depression seemed exceedingly deep, but not triangular. The ligamentum teres was exceedingly long, and capsular ligament capacious.

Summary

Congenital dislocation of the hip is produced, I believe, by injury at birth; injury *in utero*, or disease *in utero*; rhachitis; hereditary influences, and, in exceptional cases, if such there are, by arrest of development of the acetabulum.

Many of the pathological specimens reported, after excisions for old dislocations, demonstrate that the acetabulum ceases to develop and undergoes atrophic change after the head of the bone has been dislocated. It is easy to conceive of disease attacking one or both hips *in utero*, producing effusion into the joint, with or without destruction of the head; resulting, through reflex spasm of the muscle, in dislocation of the head of the femur, which is frequently seen in hip-joint disease.

I am inclined to believe, judging from the pathological specimen here presented, and from the case of dislocation at childbirth which I saw, together with pathological specimens which have been reported by Mr. Adams, which I have personally examined in the Pathological Museum in London, that the deformity is more frequently produced by violence of some description, or by pathological changes the result of inflammation, than from any other cause.

We are all familiar with the “loose joints” in certain individuals who are capable of producing dislocation of almost every joint in the body. I now have a patient who can easily dislocate the right hip and reduce the dislocation, and it gives her no inconvenience.

Given this condition *in utero*, slight causes would suffice to dislocate the head of the bone. If this occurred early in intra-uterine life, the child would probably be born with congenital dislocation and an undeveloped or absent acetabulum.

If the head of a bone has long been dislocated, the surgeon finds when he performs an excision that the joint itself is filled with new material. I have observed this in the excision of the shoulder-joint, performed for old dislocation of only six months' standing.

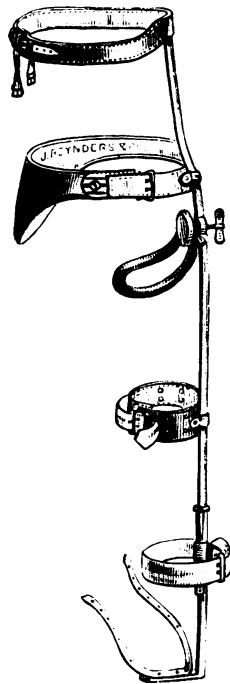
If a dislocation occurs in a rapidly-growing foetus, on account of hereditary causes (a long relaxed ligament), or by violence in child-birth, and the deformity is not discovered until the child begins to walk at the age of fifteen months, it should be expected that the acetabulum would be absent or undeveloped.

Treatment

The treatment is divided into mechanical and operative. Complete excision of the joint has been performed and good results reported.

Cutting down and making a new acetabulum in the dorsal of the ilium and nailing the head of the bone into it, has met with some favor.

Fig. 5



These two operations are advisable only in adults or in children over seven or eight years of age.

The operation of Hoffa, of Würzburg, in small children seems to me the most rational one to perform. He makes an incision down on to the head of the bone; scoops out the acetabulum, cutting deeply into the bone, and reduces the head to its normal condition. He claims excellent results from this.

The operation is performed only on children under five years of age, and where it is an impossibility to pull the bone down to the old acetabulum.

Operations of this magnitude are serious, and must be attended with considerable mortality. Still, the results of mechanical treatment in the past have been so discouraging that the surgeon now feels justified in performing any of the operations which promise satisfactory results.

The mechanical treatment of hip-joint disease has always been unsatisfactory until the case of Mr. Buckminster Brown, of Boston, was reported. This case was perfectly cured, with perfect motion, without shortening. It was treated in bed for two years by extension and great care in manipulation.

The French have long treated their cases in bed, and have reported very good results. They have also devised very ingenious appliances for making extension and still allowing their patient motion of the hip-joint. After the patients have been treated for a length of time in bed, they are allowed to exercise in a wheel-chair.

Adams improved upon this method of long confinement in bed by devising a bed in which extension could properly be applied and the limbs held in the normal position. In this

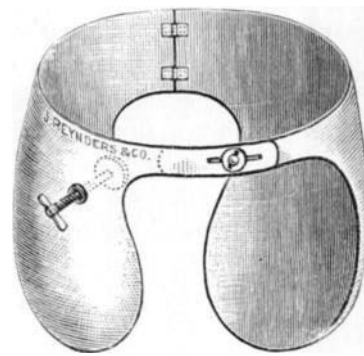


Fig. 6

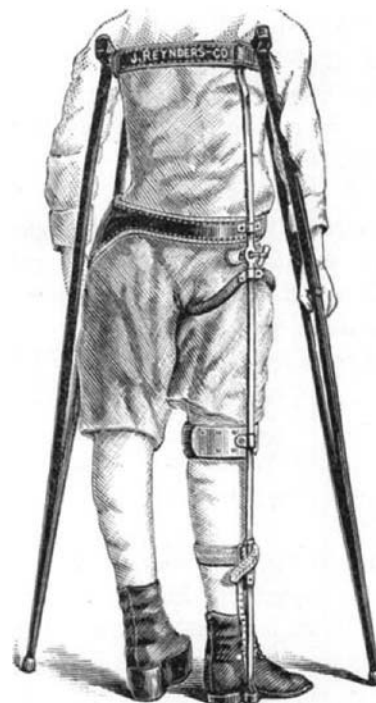

Fig. 7

the patients could be carried into the open air daily. This is simply a form of portable bed.

Sayre and Taylor, in fact nearly all of the American orthopedic surgeons, have treated such cases with the long traction hip-splint. but I must say, judging from my own observations and those of others, that the results of this plan of treatment have been most unsatisfactory. The patient would wear the splint for years, and when removed there would either be a relapse, or one limb would be found to be considerably shorter than its fellow.

I believe that the treatment of congenital dislocation of the hip should be divided into three stages :

1. The period in bed.
2. The period with the long fixation splint with a lateral-pressure screw. (See Fig. 5.)
3. The period with the walking-splint.

The length of the period of bed-treatment should be until the limb is drawn down to the length of its fellow, if possible. During this treatment by extension the patient is put into steel breeches (see Fig. 6), which have a lateral-pressure screw fitted to a pad which makes pressure over the great trochanter; the object being to excite a certain amount of irritation which will result in the growth of new tissue around the head of the bone.

After the limb has been drawn down to its normal length, which will take usually from two to six months, the patient is put on crutches, with a high shoe and a fixation splint with lateral pressure, as seen in Figs. 5, 7.

The patient is never allowed, during this stage of treatment, to step upon the brace, but after a year or a year and a half the upper part of the brace is cut off, the high shoe is lowered, and the patient allowed to walk upon the splint.

Small children I treat with the plaster-of-Paris portable bed.

Discussion

Dr. Henry Ling Taylor, of New York, said that there were at least two classes of congenital luxations at the hip, viz., those in which the luxation is produced at the time of labor, and those in which the condition is caused by an arrest of the growth of the acetabulum. He had had a case in which the luxation was unilateral, and in which there was a history of version and forcible delivery by traction on the luxated extremity. About six years ago he had presented to the New York Pathological Society a specimen of congenital dislocation which he had removed from a middle-aged man. In this case, not only were the acetabula shallow and narrow, but the entire pelvis was very light, and portions of the bones were as thin as an eggshell. Beside these, there was a fissure of the sacrum, giving additional evidence of the imperfect development of the whole pelvis.

Dr. N. M. Shaffer, of New York, had had two cases of unilateral congenital dislocation in children, which he had treated by the straight traction splint until the maximum amount of lengthening had been obtained, when a modified apparatus with a joint at the knee and a perineal support was employed. The best result had been obtained in a case which he had seen with Dr. Sands, and in which an attempt was made under ether to reduce the dislocation. After using considerable force this plan of reduction was found not to be feasible, but the manipulation produced, so to speak, an adhesive inflammation which was beneficial, and at the end of two years there was only about half an inch of shortening and a very firm joint.

Dr. Charles C. Foster, of Cambridge, said that the best recorded result had been obtained in the case treated by

Dr. Brown. He had assisted in the treatment of that case, and could speak very positively of the great amount of faithful, patient work which had been required to bring about this result. The child belonged to a family a number of whose members had loose joints. The femur could be rubbed all over the pelvis, and there was an acetabulum so slight as to be almost inappreciable. The child was put to bed and pressure applied to keep the bone in the acetabulum, and then by an arrangement of straps the limb was exercised in this position several times every day. As soon as there was evidence of deepening of the acetabulum these exercises were modified. No splint was used at any time, but when the child was removed from bed it was placed in a sort of go-cart, supported on a saddle, so that it could be allowed very gradually to bear more and more weight upon the foot.

Dr. Samuel Ketch, of New York, said that about two years ago he reported in Keating's *Encyclopædia of the Diseases of Children*, about fifty-six cases of congenital dislocation of various joints, discussing in succession the bearing upon this condition of heredity, parturition, location, and treatment. Heredity did not appear to be an etiological factor. The vast majority of labors in these cases were absolutely normal, showing the fallacy of the old idea advocated by Mr. Brodhurst concerning parturition as a cause. In this collection of cases there were no anterior dislocations. He had been unable to determine whether these cases were examples of simple malformation or of lack of development. One case was very remarkable, inasmuch as it was an instance of congenital dislocation of almost every joint in the body. In this boy there were decided evidences of rickets. Regarding mechanical treatment, he was of the opinion that our chief aim should be to improve the gait, and secure a new position for the head of the bone giving greater length to the extremity. An ordinary long traction splint with the addition of a pad and surcingle to hold the head of the bone in position will prove satisfactory in most cases.

Dr. Albert Hoffa, of Würzburg, said that the best that could be obtained by mechanical treatment was to pull down the head of the femur, and so improve the patient's gait. He thought the best results would be obtained by operation. The chief impediment to reduction is the shortening of the muscles running from the pelvis to the leg, owing to the trochanter major being nearer to the iliac crest than in the normal subject. The posterior leg muscles are also shortened. The reduction in adult cases is so difficult that he would not advise attempting operative reduction in patients over eight or ten years of age. In children of from three to six years, the reduction is very easy. After cutting off the joint and separating all the soft parts from the upper end of the femur, it is very easy to pull down the femoral head until it is in the position of the old

acetabulum. It is desirable next to enlarge this acetabulum. It has been said that it is impossible to do this, but by reference to the specimen exhibited by Dr. Phelps, it will be seen that the acetabulum is the thickest part of the pelvis, and there is no difficulty whatever in making a sufficiently deep acetabulum. In his first operations he used a periosteal flap which he sewed over the trochanter major, but subsequently he found that it was not necessary to make this flap, for, if the cavity be sufficiently deep, there is no danger of the head of the bone coming down. The chief feature of his operation consisted in saving the head, and thereby obtaining a healthy joint. His first operations were performed about two years ago, and about two months since he examined the first case and found a perfectly movable joint and the absence of the awkward gait characteristic of congenital dislocation. Even lordosis was absent. In all of his cases he had found a rudimentary acetabulum, which was triangular in shape. Some cases had been reported in France in which the site of the acetabulum was occupied by an exostosis, but no such condition had existed in any of his cases.

Dr. Howard Marsh, of London, England, called attention to the statement which had been made concerning the absence of any causal relation between these dislocations and heredity. He did not consider that this remark correctly represented the subject, for, many years ago, he had had a case of congenital dislocation of the hip brought to him whose mother also had the same condition with very free telescopic movement on the pelvic wall. The condition found in the child was exactly similar to that shown in the specimen just presented. The anterior position is the most favorable one because in these cases there is no lordosis, for the lordosis depends upon the extent to which the femur is displaced backward upon the walls of the pelvis. Congenital dislocations should be divided into (1) those in which the bone slips about on the walls of the pelvis, and (2) those in which it is fixed. In the majority of cases it is so fixed, and under these circumstances he did not think operative measures should be undertaken. Such measures were more properly applicable to cases where the head of the femur is high up and movable.

Dr. John Ridlon, of New York, had had an opportunity of seeing one of Dr. Phelps's cases. He had also had two cases of this condition in his own practice, and he desired to direct attention to the uselessness of mechanical treatment. Dr. Brown's case was a posterior one and the result was good, and this was what might be expected. In his own first case, after the use of traction by the Taylor splint in bed for a year, until the shortening had been reduced, on placing the head of the bone over the acetabulum the entire limb was rotated inward about 90 degrees. In the process of growth from birth to the age of eleven years a distortion of the neck had occurred, and, therefore, simply replacing

the bone only resulted in placing the feet at right angles—a worse condition than at the beginning. In these cases mechanical treatment is obviously of no benefit. He thought anterior dislocations more hopeless than posterior ones under mechanical treatment.

Dr. R. H. Sayre, of New York, had had a case of dislocation on the dorsum of the ilium. Here he had brought down the head on to the acetabulum, but it now had a tendency to become a pubic dislocation. He uses an instrument similar to the long traction splint, but with a joint at the pelvis, so that the head can, if desired, make movements at the hip joint with the idea of assisting in creating a new acetabulum. He thought with Dr. Foster that a grinding motion is an important factor in securing such a result, provided the head of the bone could be retained in the proper position. The iron ring in Dr. Phelps's apparatus he did not think would prove as good in practice as a strap, which could be removed from time to time. The cases in which the bone remained in a fixed position were best let alone.

Dr. E. H. Bradford, of Boston, referred to a case which he had reported on a previous occasion in which he had been using a very light portable splint, which he desired to exhibit to the Association.

Dr. De Forest Willard, of Philadelphia, considered the movable cases the most hopeful ones for operation. In cases where there is slight movement it is better to combine operative and mechanical treatment, beginning first with rather forcible attempts at reduction in order to produce inflammation, and then making continuous horizontal traction, as well as employing systematic exercises with the idea of exciting sufficient inflammation to hold it in place. Lastly came the use of a retaining splint.

Dr. L. A. Weigel, of Rochester, during the past two years had seen three cases of congenital misplacement, two of them being unilateral, and in all of them, by simple traction upon the leg, the limb could be brought down to the normal length, and there was a perceptible play on striking the rudimentary acetabulum. In some cases the muscles on the affected side were rather imperfectly developed. He did not think that in old cases the shortening could be overcome.

Dr. Phelps, in closing the discussion, said, regarding the etiology, he had traced cases and had found that heredity appeared to play an important part. After his splint has been worn for a year the upper part of it is removed to allow of motion, and the patient walks upon it, discarding the crutches. The vast majority of the cases he believed were really dislocations *in utero* or at birth with subsequent non-development of the acetabulum, and not congenital non-development of the acetabulum allowing of misplacement of the head of the femur, as has been taught and still is believed by a large portion of the profession. The pathological specimen presented appeared to confirm that idea.