

## The Classic

### Ankylosis: Arthroplasty—Clinical and Experimental\*

John B. Murphy AM, MD

Published online: 30 August 2008



Dr. John B. Murphy is shown. Reprinted with courtesy from Davis LJB. *JB Murphy: Stormy Petrel of Surgery*. New York, NY: G.P. Putnam's Sons; 1938.

This month we republish abridged sections from Dr. John B. Murphy's article, "Ankylosis: Arthroplasty-Clinical and Experimental," published in 1905 [6]. Dr. Murphy, quite a controversial figure in his time [3], made many innovations in many surgical fields. Dr. Murphy was born in Appleton, Wisconsin in 1857, to a farming family who had immigrated from Ireland [3, 8]. He graduated from high school, having been sufficiently accomplished he taught some of the courses [7]. He apprenticed with a local surgeon, and in 1878 at the age of 21 entered Rush

Medical College [3]. His mentor, Dr. Christian Fenger, encouraged him to go abroad, which he did for a period of two years beginning September, 1881 [3]. He visited London and Paris on his way to Vienna, Berlin, and Heidelberg, spending time with Billroth, Schröder, and Arnold in those three centers. He returned to Chicago in the spring of 1884 to a private practice and became a professor of surgery at Rush Medical College and the Northwestern Medical College. His accomplishments and prominence were such that he became Chief of the Editorial Staff of *Surgery, Gynecology, and Obstetrics*, then President of the American Medical Association in 1911. Dr. Murphy was a founder of the American College of Surgeons and honored by membership in The Royal College of Surgeons of England and receiving a Knighthood in the Order of St. Gregory. He died of heart disease in 1916.

The article we republish in an abridged version outlines the embryological basis for joint development and the experimental and clinical basis for joint reformation using various forms of arthroplasty in stiff or ankylosed joints. Based on the manner of joint formation embryologically, Murphy explained the development of a "hygroma"—a space with "acquired endothelial lined sacs." Such spaces provided the rationale for arthroplasty, and he, as others he cites, recognized the importance of interposing various materials to facilitate such formation. These materials included skin, fascia, muscle, periosteum, and adipose tissue. However, he noted Chlumsky experimented with artificial materials such as "plates of celluloid, silver, zinc and rubber, cambric, and layers of colloidion" while Hubscher used

magnesium foil. "Interposition arthroplasty" was common well into the mid 20th century. Campbell described various forms of the procedure, and noted that prepared animal membranes, including chromacized pig's bladder, were no longer in general use in 1939 [2]. By that time metals, including Vitallium as advocated by Smith-Petersen for hip interposition arthroplasty [11], had become more widely accepted. All authors, up to and including Murphy, recognized the importance of the aftercare, including passive and active motion, and occasionally forced manipulation. For the time, the outcomes were sometimes remarkably effective compared to the disability of the stiff joint, although we have no idea as to the success rates since series were virtually never reported and failures rarely. The concept, though, remains current for many uses: the carpometacarpal joint [10], following resection of the distal ulna [4], temporomandibular joint [5], elbow [9], shoulder [1], and other joints.

Richard A. Brand MD

## References

- Adams JE, Steinmann SP. Soft tissue interposition arthroplasty of the shoulder. *J Shoulder Elbow Surg.* 2007;16:S254–260.
- Campbell WC. *Operative Orthopaedics.* Saint Louis, MO: C.V. Mosby Co; 1939.
- Davis LJB. *J. B. Murphy: Stormy Petrel of Surgery.* New York, NY: G.P. Putnam's Sons; 1938.
- Greenberg JA, Sotereanos D. Achilles allograft interposition for failed Darrach distal ulna resections. *Tech Hand Up Extrem Surg.* 2008;12:121–125.
- Mehrotra D, Pradhan R, Mohammad S, Jaiswara C. Random control trial of dermis-fat graft and interposition of temporalis fascia in the management of temporomandibular ankylosis in children. *Br J Oral Maxillofac Surg.* 2008 Apr 15. [ePub ahead of print].
- Murphy JB. Ankylosis: Arthroplasty-Clinical and Experimental. *JAMA.* 1905;27:1–77.
- Murphy JB. Classical articles in colonic and rectal surgery. Cholecysto-intestinal, entero-intestinal anastomosis, and approximation without sutures. *Dis Colon Rectum.* 1981;24:51–59.
- Murphy JB. The classic. Arthroplasty for ankylosed joints. By John B. Murphy. 1913. *Clin Orthop Relat Res.* 1986;213:4–12.
- Nolla J, Ring D, Lozano-Calderon S, Jupiter JB. Interposition arthroplasty of the elbow with hinged external fixation for post-traumatic arthritis. *J Shoulder Elbow Surg.* 2008;17:459–464.
- Schibli-Beer S, Mark G, Canova M. Results after simple trapeziectomy and capsular fixation for osteoarthritis of the trapeziometacarpal joint [in German]. *Handchir Mikrochir Plast Chir.* 2008;40:169–174.
- Smith-Petersen MN. Arthroplasty of the hip: a new method. *J Bone Joint Surg Am.* 1939;21:269–288.

© The Association of Bone and Joint Surgeons 2008

The Classic Article is ©1905 and is abridged and reprinted from Murphy JB. Ankylosis: Arthroplasty-Clinical and Experimental. *JAMA.* 1905;27:1–77.

\*Read before the American Surgical Association, St. Louis, 1904.

Richard A. Brand MD ✉  
Clinical Orthopaedics and Related Research,  
1600 Spruce Street, Philadelphia, PA 19103, USA  
e-mail: dick.brand@clinorthop.org

The subject of ankylosis and its treatment presents many problems for consideration. In order immediately to emphasize the salient points of the subject, we will ask some questions: What are joints? What is the embryology of joint formation? What is the pathologic histology of acquired arthroses or false joints? What is the pathology of hygromata (acquired endothelial lined sacs)? Can they be produced artificially? What is ankylosis? What are the pathologic and anatomic changes included in the term? What tissues are involved? From a practical standpoint, into what classes may it be divided? When ankylosis has formed, what are the limitations of surgery for its relief? Can we re-establish a movable, functioning joint with synovial lining? Can we restore motion and to what degree? In what class of cases can the best results be secured? Can we for the future promise better than the flexible, fibrous unions that we have secured in the past?

These were the questions that most forcibly presented themselves when I began the investigation of this subject in July, 1901. Subsequent experience has shown that, from a clinical standpoint, the majority of these have been answered favorably. Experimental work on joints in dogs is unsatisfactory on account of the difficulty in controlling infection and motion. A preliminary report of this work with demonstration of one of the cases was made to the Chicago Surgical Society at Mercy Hospital, October, 1902.

## Embryology of Joints (Section Not Republished—Pages 2–14)

### Ankylosis

Ankylosis is a generic term and does not represent a pathologic entity. It is due to varied pathologic conditions... In the

particular variety, in which the capsule is the seat of the disease which produces the immobilization of the joint, the capsule is infiltrated, indurated and adherent throughout the margin of the joint, thus limiting the motion. The extracapsular varieties include the inflammations and adhesions of the tendons and tendon sheaths, as well as the muscular agglutinations, at and close to the joint. They may not include the capsule at all, the entire restraining structure being extracapsular. These lesions differ entirely from the articular variety of ankylosis, in which the lesion is in the synovial membrane which has lost its endothelial lining and has undergone fibrosis and transarticular union.

The cartilaginous variety exists when the synovial membrane has undergone complete destruction, and when there is a union of the cartilage or cartilaginous remnants with no vestige of the synovial structure remaining.

The most serious type of ankylosis is that in which the synovial membrane and cartilage both have disappeared and in which osseous union has taken place between the opposing bone ends.

The last three types of ankylosis will more particularly concern us in this paper.

### Arthritis (Section Not Republished—Pages 15–21)

#### Treatment

Treatment must be directed against anyone of the following types of anatomic pathologic conditions:

- A. Extra capsular disease
  1. Tendon elongation—(tendoplasty),
  2. Tendo vaginitis (exsection of sheath),
  3. Cicatrices—removal
- B. Capsular
  1. Adhesive synovitis—exsection of capsule,
  2. Replacement b aponeurosis or muscle,
- C. Osseous
  1. Disconnect bones,
  2. Remove neighboring bony processes or prominences,
  3. Liberate soft parts,
  4. Prevent subsequent bony contact,
  5. Interpose tissue to form hygroma or fibrous surface,
- D. Joints suitable for operation
  1. Mandibular,
  2. Hip,
  3. Shoulder,
  4. Elbow,
  5. Knee,

#### E. Technic

1. Flap formation—skin flap with fascia or muscular,
2. Exposure of ankylosed area,
3. Osseous separation,
4. Transplantation and fixation of interposition flap,
5. Replacement of bone,
6. Fixation of parts,
7. Drainage,

#### F. Subsequent treatment

1. Passive motion,
2. Active motion,
3. Forcible extension,

#### G. Prognosis

1. Mandible,
2. Hip,
3. Shoulder,
4. Elbow,
5. Knee

The treatment of ankylosis in the past may be classified as the forcible separation of the adherent surfaces, and endeavor to maintain motion after the adhesions had once been freed (*brisement*). In a very small percentage of the cases, namely, those of synovial adhesion without organic union, the result was gratifying. In the enormous percentage of cases in which the lesions were due to necrosis of the synovial membrane or to fibrous or osseous union of the articular surfaces, ankylosis recurred after *redressement*, and the limb was in as bad, if not in worse, condition than before.

Schuh, in 1853, mobilized the patella with the chisel by cutting the synechia, but interposed nothing, and the ankylosis recurred. Cramer [8] says that operations in which the adhesions were separated by forcible distension (Ollier), by the mallet (Hueber), or by the chisel (Schuh) rarely have been successful, and that the Brachi method of establishing movement of the patella by manipulation is equally unsatisfactory.

Helferich, in 1899, proposed to free the patella with a chisel and to interpose part of the vastus internus between the patella and femur to prevent adhesion. He did not perform the operation.

Cramer [9] saw 10 cases of ankylosis of the patella, in seven of which he operated by interposition of the vastus internus; six operations were successful. This does not imply ankylosis of the knee joint, but of the patella alone.

Verneuil [10] and Helferich preceded him in this idea, both in suggestion and performance, by the interposition of portions of the muscle and fascia in temporomaxillary ankylosis.

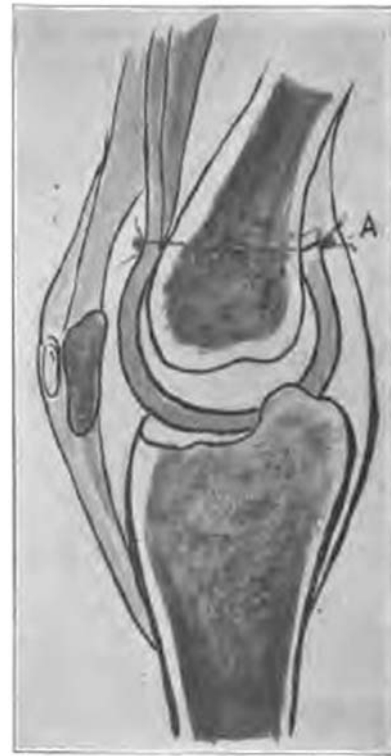
Chlumsky [11] states the following: “The treatment of complicated contractures and ankyloses of the joints as far as *restitutio ad integrum* is concerned gives very unsatisfactory results. I have collected 14 cases of ankylosis, other than tuberculosis of the knee joint, with contraction, which occurred in the last 10 years in the Breslau Surgical Clinic and were there treated, and in not a single case was there improvement in the mobility of the joint.” He found also no better results recorded in the literature on the joints, and for that reason undertook experiments in the endeavor to clear up the question. He then attempted, through forcible extension and flexion repeatedly done under anesthesia, to secure mobility of the joint. After each trauma there were additional deposits of osseous and fibrous tissue, and the cases were uniformly worse after than before the operation. He reasoned that the interposition of muscle or fascia, such as takes place in pseudoarthroses after fracture, should give good results. Good results along this line were obtained by Mikulicz, Helferich, Lenz, and Riegner, and, with this knowledge, Chlumsky concludes that in large joints this procedure is not possible, either through failure of preservation of the interposed part or on account of technical difficulties. (Fig. 37. Editor’s Note: this figure is not from Chlumsky or the other authors but rather one of Murphy’s cases from deleted material; it is shown here only to illustrate the procedure.)

Not satisfied to abandon the field, he decided to resort to the interposition of foreign bodies and conducted a large number of experiments. The materials used were plates of celluloid, silver, zinc and rubber, cambric, and layers of collodion, and, while he succeeded in retaining mobility with these interposed materials in some cases, a fair preservation of the articulation beyond 4.5 months was not obtained. The ankylosis ultimately occurred and the foreign body became extruded from the joint. He, therefore, concluded to substitute, for the unabsorbable material, absorbable material, such as decalcified bone, ivory, and magnesium. In these cases, at the end of from 3 to 12 weeks, he found various degrees of absorption and in some a moderate attempt at the formation of a joint, but with very unsatisfactory results on the whole.

At this period, Oct. 5, 1901, I performed my first operation, Mr. D. (full particulars given under the heading of “report of cases”).

Hubscher [12] used magnesium foil, 5 mm in thickness, in ankylosis of the patella. Speaking of the different methods and experiments, he mentions Bruns, who has successfully transplanted the flexor tendons after 5 years of immobilization by adhesions. He failed to secure freedom of the patella.

McIlhenny [13] operated for temporomaxillary ankylosis by osteoclasia and the formation of a new joint. The details of the operation were as follows:



**Fig. 37** Case 10: Sagittal section through knee joint, showing entire articular surface of femur covered by fascial flap, which is sutured to periosteum at A.

An Esmarch incision was made on the right side, exposing the jaw bone from the sigmoid notch to a point a little anterior to the angle. The masseter was retracted and a wedge of bone, 0.5 inches in diameter, was removed from the neck of the condyle just above the insertion of the external pterygoid. The same procedure was followed on the opposite side, with the result that the mouth could be opened to almost normal. The tongue was found attached and was carefully freed. The ends of the bone were rounded off and the cavity was packed with iodoform gauze. Fibrous bands in the side of the mouth gave trouble and these were stretched, divided by tenotomy and the external wound finally closed. The patient was able to chew for the first time in 15 years. (From the description of this case I infer that the union was a fibrocartilaginous one and not the formation of a new joint.) Shortening the neck and removing the head of the mandible allowed the temporal and masseter muscles to act as a pivot on which the jaw revolved. The practical result was excellent.

Gluck, of Berlin, at the 31st Congress of the Deutsche Gesellschaft für Chirurgie (Berlin, April 2–5, 1902), presented a little girl whom he had treated for gangrenous stomatitis and septic phlegmon of the mouth. The alveolar process and the teeth were gone. The cicatricial tissue was removed after Gussenbauer’s method and a flap of skin transplanted into the mouth. He referred to two other cases

of bony ankylosis of the temporomaxillary articulation. The joints were mobilized and the wound was tamponed. Ten days later, with the hammer and chisel, portions of the bone were removed. A cutaneous wedge was implanted, with attachment to the bony surfaces, to interpose and prevent union. The wound healed; the mouth could be opened to the maximum. He believes the cutaneous flap is the best for this purpose. He promised a more complete report later, which did not appear.

A. Blencke [14] advocates conservative treatment of these joints with the apparatus of Lorenz and Helferich. Calot does not believe in force or violence in the restoration of motion in ankylosed joints.

Golebiewski recommends his apparatus for the treatment of ankylosis and says he has obtained very good results. (If by this he means good results where bony or fibrous ankylosis existed and the synovial membrane and cartilage had been destroyed, it does not correspond with our knowledge of the process of repair of these surfaces under such circumstances. I, therefore, believe that he must have referred to the purely adhesive cues of arthritis.)

In treating ankylosis the points to be considered are the type of ankylosis, the tissues involved, and the pathologic lesion producing the ankylosis.

(Pages 26–31 not republished)

In general the elements which have contributed most to the failures have been:

1. The insufficient or defective exsection of the synovial membrane, capsule, and ligaments.
2. Insufficient interposition of fat and aponeurosis, or of fat and muscle, between the separated bony surfaces.
3. Infection.
4. Sensitiveness to pain on motion after operation.

Where osseous union has existed, it is important to disconnect the bones in as nearly their normal line of union as possible. This can be done with the narrow chisel better than with the saw. In the shoulder and hip the chisel can be used to separate the bones so as to outline the line of fracture as deeply as is necessary to secure nearly the normal conformation both of the head and cavity. All bony prominences that may impinge against other bones in extreme degrees of motion should be removed; for example, the coronoid process and the tip of the olecranon process. The soft parts should be liberated most thoroughly. It appears a repetition; but it cannot be too forcibly impressed on the operator that this is essential to a good result, and muscular aponeurosis with fat makes the best interposed tissue. If the aponeurosis cannot be found, then the muscle and some fatty tissue should be substituted, as the muscle, when subjected to pressure, gradually flattens out into an aponeurosis in many joints, but it does not well withstand the early pressure which is necessary to a good result.

(Pages 32–69 not republished; this consists of 12 case reports from Murphy's practice)

The history of the formation of new joints begins with J. Rhea Barton [15], of Philadelphia. To him belongs the honor of the first attempt (in 1826) to rectify an angular, true ankylosis of the hip joint by osteotomy. Briefly, his operation consists in incision of skin and muscles and division of bone through the great trochanter and a part of the neck of the femur; then preventing bony union by movements, which will induce ligamentous attachment only.

Dr. J. Kearney Rodgers, of New York, modified his operation in 1830 by removing a disc of bone from between the trochanters.

In 1838 A. Bérard [16], writing on ankylosis of the temporomaxillary joint, advised the method of Rhea Barton—section of condyles and prevention of bony union by means of motion, in order to form a false and new joint.

John Murray Carnochan, of New York, claims to have performed, in 1840, for the first time, an operation in order to establish a new joint, formation of a “maxillary pseudarthrosis.” In operating on a case with ankylosis of the temporomaxillary joint he fractured accidentally the maxillary, which suggested to him later the advantage of dividing the maxillary in order to create a pseudarthrosis of the maxillary joint. In this case he tried to prevent bony union by interposing a piece of wood between the cut bony surfaces. He also advised the patient to chew. The technic followed by Carnochan consisted of division of the temporal and masseter tendons, section of the ramus, and prevention of bony union by interposing cotton. (The bone should be divided through the mouth).

In his “Lectures on Surgical Anatomy and Operative Surgery” he showed that in some cases of ankylosis of the temporomaxillary joint subcutaneous tenotomy of the masseter and temporal is practicable and rational.

Dieffenbach [17], in his operative surgery, mentions the treatment of ankylosis of the temporomaxillary joint by “section of bones.” On page 774 of the same work he advises section of the masseter and formation of a new joint in cases of ankylosis of the temporomaxillary joint.

Esmarch is one of the surgeons who also recommends the creation of pseudarthrosis in ankylosis of the temporomaxillary joint. He advises surgical intervention only in cases where the immobility is due to cicatricial tissue; in other words, he does not operate on joints with any structural changes.

In his thesis Charles Richet [18] advises the following technic in cases of ankylosis: Longitudinal incision of periosteum, which is denuded and preserved “in order to form the new articular capsule.” He then divides the bones and advises the patient to chew, so as to prevent bony union.

Rizzoli and A. Verneuil [10] restored motion—the former in three cases, the latter in one of temporomaxillary ankylosis—by section of both extremities and prevention of union by movements. The result was a pseudarthrosis.

### Joints by Muscular Interposition

Recently the ankylosis of joints has been corrected by osteotomy, followed by muscular interposition...A case of ankylosis of the shoulder joint was treated by muscular interposition by M. Coville (case reported by Nélaton). A young woman, 22 years old, had absolute ankylosis of the shoulder joint, following trauma. On May 19, 1903, Coville made a 4-inch incision, starting below the clavicle and passing externally to the coracoid process; then down the arm, following the fibers of the deltoid. The muscle was incised outside of the groove separating it from the pectoralis. The head of the humerus was extruded and divided at the level of the anatomic neck. The long strip of the deltoid was cut transversely, the superior part being left adherent. A piece of 4 inches, obtained by the transverse section, was interposed between the surface of the humerus and glenoid cavity. Coville perforated the capsule with a probe so as to prevent wounding the musculo-spiral nerve. A counter incision was made at the same level and a thread passed through this opening, surrounding, in the form of a loop, the extremity of the muscular strip, and by tightening it applies the muscle in the articular cavity. Three days later movements of the new joint were performed.

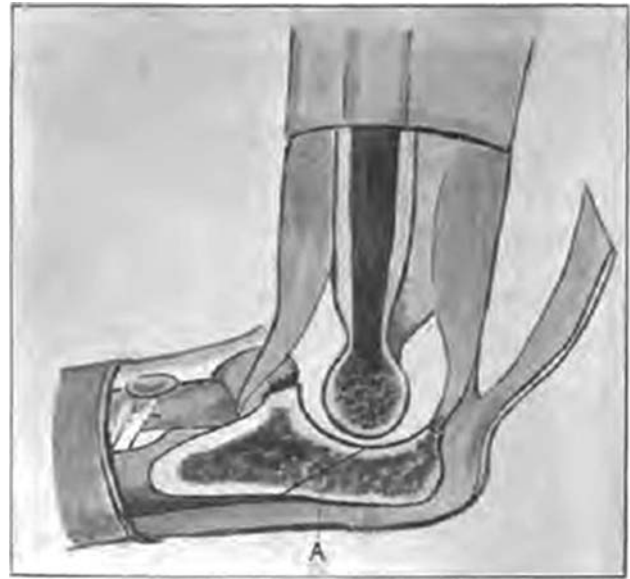The result was good; the woman was able to sew (she was a tailoress), but abduction was limited.

(Portions of pages 75–76 not republished)

Some surgeons advise another operation for ankylosis. T. Wolff reported nine cases of ankylosis in 1896 and 1897 in the *Berliner Chirurgen Vereinigung*. He made use of “arthrolysis:” section, chisel, and excision of all the fibrous tissue which hindered movement. The operations were followed by good results.

Eiselsberg reports good results in only one of the two joints in which he used the same method. Kocher, while in favor of arthrolysis, modifies it by putting the bony extremities, after the arthrolysis, in a position of dislocation, which he reduces 8 to 14 days later.

Quénu (Société de Chirurgie, Paris, June 25, 1902) reported a case of ankylosis of the elbow joint treated by interposition of soft tissues after an extensive resection of the bony extremities. (Fig. 34. Editor’s Note: this figure is not from Quénu but rather one of Murphy’s cases from



**Fig. 34** Sagittal section through elbow joint. Olecranon is detached from ulna through oblique line. (A) Fascial flap shown with pedicle below.

deleted material; it is shown here only to illustrate the procedure.) He first largely resected the ends of the ulna, the radius, and the humerus and then interposed the anterior ligament of the elbow. The result was very satisfactory.

Delbet also praises the method of “muscular interposition” in cases of ankylosis.

In our work we have been able, by the interposition of fascia and muscle, covered with a layer of adipose tissue, to produce normal movable joints, with capsules and collagen intra-articular fluid. This, we believe, is the first systematic production of new and practically normal articulations.

### References (Only from Republished Pages)

8. Paper read before the 30th Congress of the Deutsche Gesellschaft für Chir. Berlin, April 13, 1901.
9. *Arch. klin. Chir.*, 1901, vol. lxiv, p. 696.
10. Verneuil, A.: *Archives de Medecine*, 1860, p. 284.
11. Chlumsky: *Centralb. F. Chir.*, Sept. 15, 1900. *Wien. Klin. Woch.*, 1902.
12. Hubscher: *Corresp.-blatt f. Schweiz. Aerzte*, Dec. 15, 1901, vol. xxxi, p. 785.
13. McIlhenney: *New Orleans Med. Jour.*, April, 1901.
14. Blencke: *Zeitz. F. orthoped. Chir.*, vol. viii, No. 1.
15. North: *Amer. Med. And Surg. J.*, 1827, p. 290.
16. Bérard, A.: *Dict. De Med. En 30 vols.*, xviii, p. 440, 1838.
17. Dieffenbach: *Operative Surgery*.
18. Richet: *Thèse de Concours; Des Operations applicable aux ankyloses*.
19. Nélaton: *Bull. et Mem. de la Soc. De Chirurgie*, 1902, p. 587.
20. Berger: *Bull. et Mem. De la Soc. De Chir.*, 1903. Vol xxix.